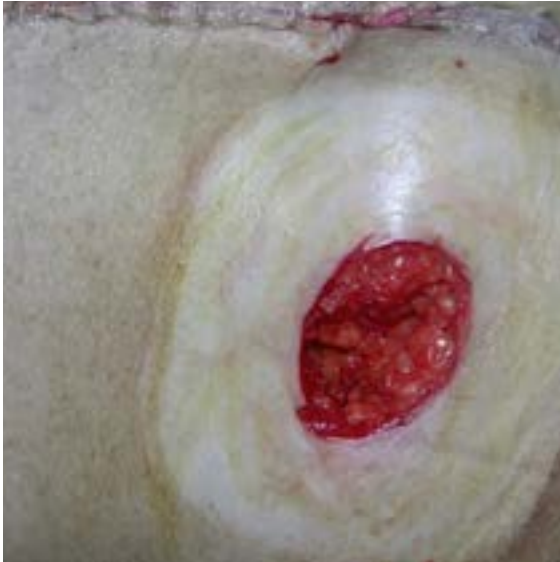
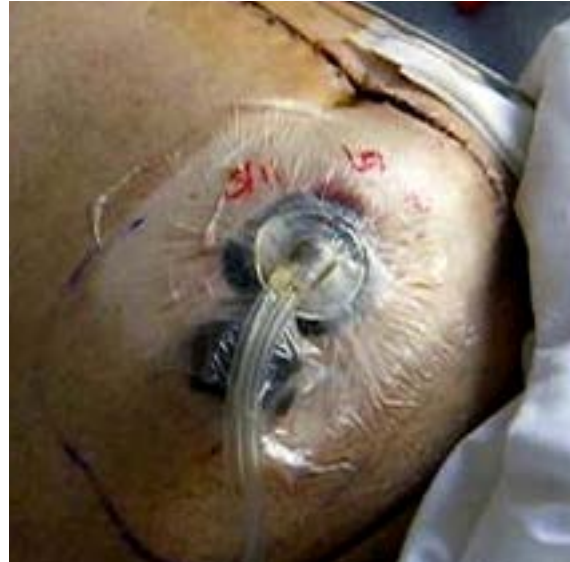
Case Study 3: Contaminated Ileostomy Site

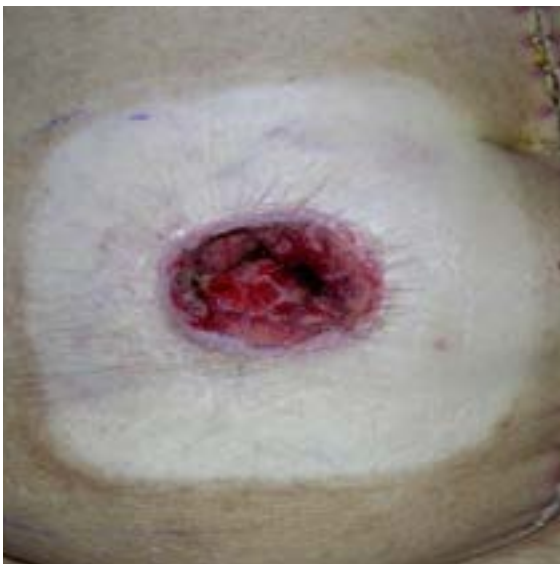An 83-year-old male presented with an open postoperative contaminated wound at a previous ileostomy site. V.A.C. VeraFlo™ Therapy was initiated using V.A.C. VeraFlo™ Dressing. Microcyn® (Oculus Innovative Sciences, Petaluma, CA) was instilled until the foam was filled followed by a soak time of 10 minutes. Instillation was repeated every 4 hours followed with continuous negative pressure at -125 mmHg for 12 days. Therapy was discontinued when patient transitioned out of the acute care setting and the wound could be treated with local wound care alone. No complications occurred during therapy.



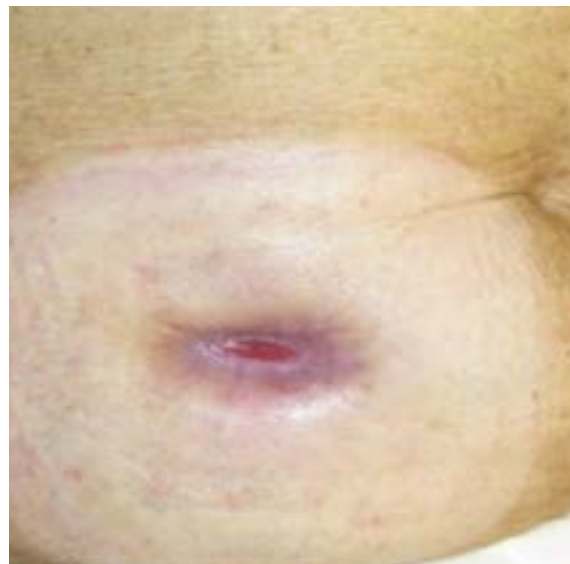
A. Immediate postoperative, right lower quadrant wound



B. Application of V.A.C. VeraFlo™ Therapy with instillation of Microcyn®



C. Day 10 of V.A.C. VeraFlo™ Therapy at 4th dressing change



D. Follow up on postoperative Day 34