

POST-OPERATIVE WOUND MANAGEMENT OF A DEHISCED AND INFECTED RIGHT THIGH LOBULE POST EXCISION

A 63-year-old morbidly obese female was admitted to the inpatient nursing unit with an infected right thigh lobule excision of a massive localized lobule (MLL) that inhibited her ability to ambulate (**Fig. A**). The resultant wound was a large soft tissue deficit and a source of significant pain. Her healing abilities were already limited due to her significant lymphedema.

Following surgical debridement of an infected hematoma in the OR on postoperative Day 10, bedside staff applied 0.25% acetic acid soaked gauze (KERLIX™ Gauze Bandage Rolls, Covidien, Minneapolis, MN) packing twice daily. She required IV narcotics for each dressing change, and it took two nurses to perform the dressing change.

After 11 days of twice daily gauze packing, there was no reduction in wound size and little improvement in pain, odor, or wound tissue type (**Fig. B**). On postoperative Day 21, retention sutures were removed, revealing a large hematoma with the wound measuring 34.5cm x 15cm x 14.5cm (**Fig. C**). V.A.C. VERAFLOR™ Therapy (KCI, an Acelyty Company, San Antonio, TX) was initiated using the V.A.C. VERAFLOR™ Dressing (KCI, an Acelyty company, San Antonio, TX); 100ml of 0.25% acetic acid was instilled with a 5-minute dwell time, followed by continuous negative pressure at -125mmHg every 6 hours.

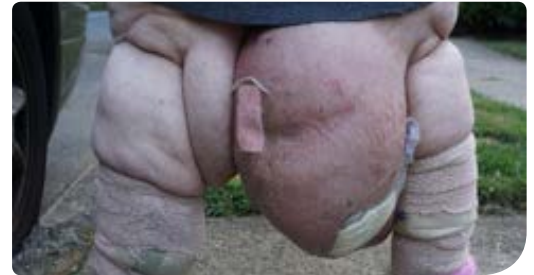

Fig. A: Pre-operative picture of patient with MLL of right thigh.

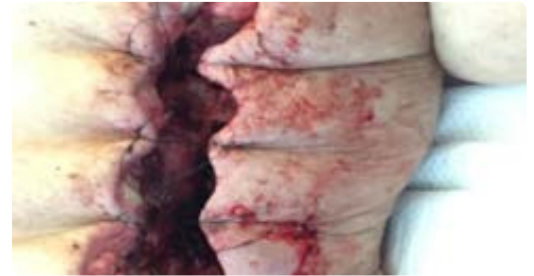


Fig. B: Postoperative Day 12. Wound presentation after twice daily packing with 0.25% acetic acid soaked gauze.

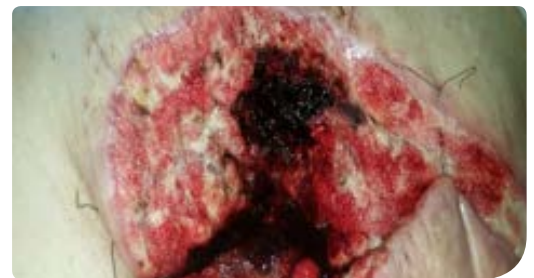

Fig. C: Postoperative Day 21. Wound appearance before initiation of V.A.C. VERAFLOR™ Therapy (100mL of 0.25% acetic acid instilled with 5 minute dwell time, followed by continuous negative pressure at -125mmHg every 6 hours).

On postoperative Day 24, V.A.C. VERAFLOR™ Therapy was continued with 80ml of normal saline instilled with a 5-minute dwell time, followed by continuous negative pressure at -125mmHg every 4 hours (Fig. D).

On postoperative Day 27, after 7 days of treatment, the wound volume was reduced to 23cm x 14cm x 9.5cm, and the patient was discharged to a rehabilitation facility (Fig. E). V.A.C.® Therapy (KCI, an Acelyty Company, San Antonio, TX) was initiated with continuous negative pressure at -125mmHg for 3 weeks. On postoperative Day 48, the patient underwent a split-thickness skin graft (STSG) for wound closure. V.A.C.® Therapy was used to bolster the STSG for 1 week, and the patient was discharged home from the rehabilitation facility with a healed wound (Fig. F).

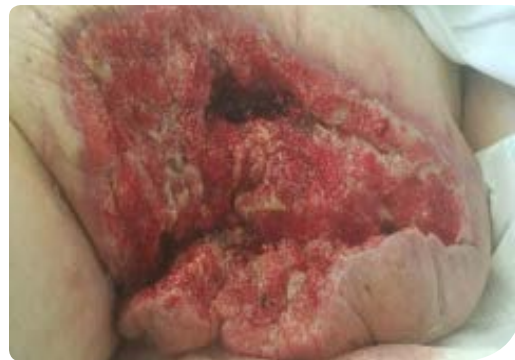

Fig. D: Postoperative Day 24. V.A.C. VERAFLOR™ Therapy was continued with 80ml of normal saline with 5-minute dwell time, followed by continuous negative pressure at -125mmHg every 4 hours.

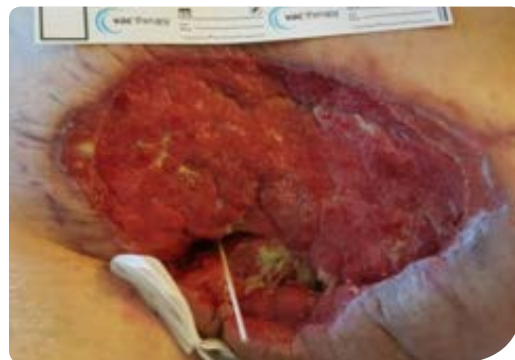

Fig. E: Postoperative Day 27. Wound appearance after 7 days of V.A.C. VERAFLOR™ Therapy.

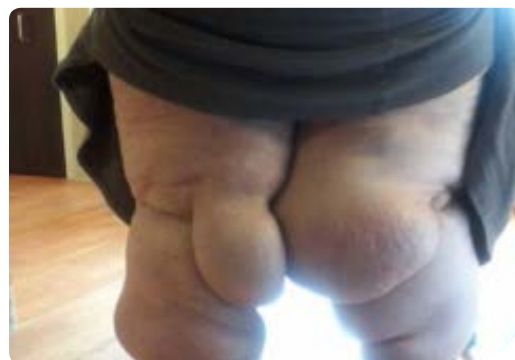

Fig. F: Postoperative Day 56. Healed wound following STSG.

Patient data and photos courtesy of Elizabeth McElroy, CRNP, CWS, CWOCN; West Reading, PA

Note: As with any case study, the results and outcomes should not be interpreted as a guarantee or warranty of similar results. Individual results may vary, depending on the patient's circumstances and condition.

NOTE: Specific indications, contraindications, warnings, precautions and safety information exist for KCI products and therapies. Prior to the use of any medical device, it is important for the provider to consult the treating physician and read and understand all instructions for use, including safety information, dressing application instructions, and therapy device instructions. Rx only.

©2016 KCI Licensing, Inc. All rights reserved. Unless otherwise designated, all trademarks designated herein are proprietary to KCI Licensing, Inc., its affiliates and/or licensors. DSL#16-0331.03.US (7/16)