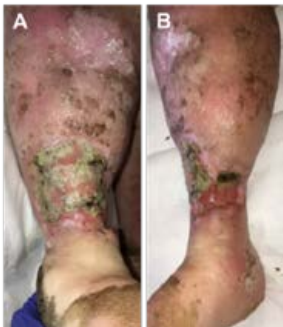

V.A.C. VERAFLOR™ Therapy with V.A.C. VERAFLOR CLEANSE CHOICE™ Dressings followed by PROMOGRAN™ Matrix Wound Dressing

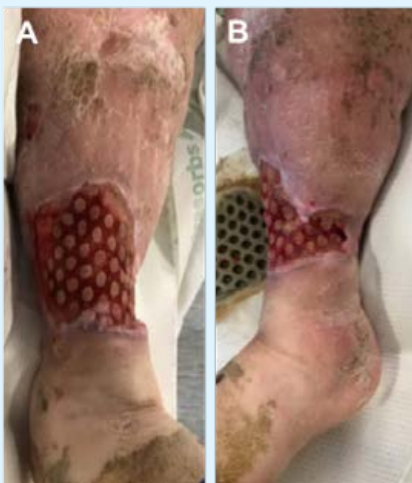Venous Leg Ulcer

Kersten Reider BSN, RN, CWOCN
 Elizabeth McElroy, MSN, RN, CRNP, CWS, CWOCN-AP
 Tower Health System, West Reading, PA



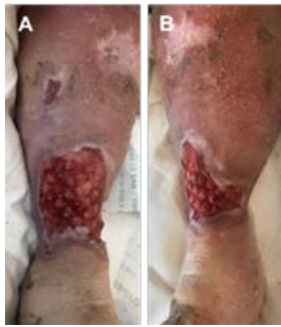A 60-year-old female presented with a venous leg ulcer present for an unknown amount of time (10 cm x 16 cm x 1.5 cm) of the right distal lower extremity (**Figure 1**). Previous medical history included peripheral vascular disease, obesity, hypertension, thyroid disease, gastroesophageal reflux disease, respiratory failure, Influenza A infection, infected right leg wound with cellulitis, and septic shock. Systemic antibiotics were initiated upon presentation. Tubular compression was utilized to assist with edema management.

Fig. 1: Venous leg ulcer at presentation. A. Anterior view; B. medial view.



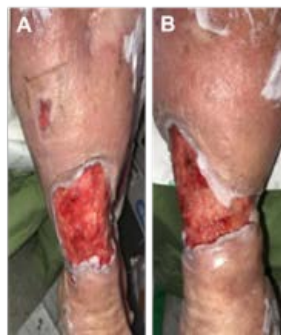V.A.C. VERAFLOR™ Therapy using **V.A.C. VERAFLOR CLEANSE CHOICE™ Dressings** were used as wound required cleansing to help remove infectious materials. Ostomy barrier paste was utilized to assist with the creation of dressing seals. The wound was instilled with **34mL of quarter strength Dakin's solution** with a **10-minute dwell time**, followed by **1 hour of continuous negative pressure (-125mmHg)**. After 24 hours, the dressing was changed, and the instillation solution was switched to **28mL of normal saline** (**Figure 2**). Dressing changes occurred every 2-3 days.

Fig. 2: Wound after 24 hours of V.A.C. VERAFLOR™ Therapy with Dakin's solution (quarter strength). A. Anterior view; B. medial view.



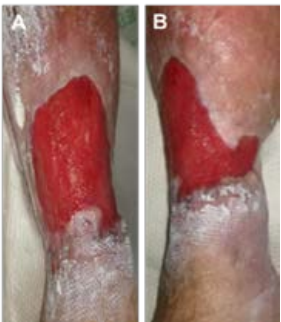After 8 days of V.A.C. VERAFLOR™ Therapy with V.A.C. VERAFLOR CLEANSE CHOICE™, the wound had decreased in size (8.6cm x 13cm x 0.2cm) and exhibited healthy granulation tissue (Figure 3).

Fig. 3: Wound after 8 days of V.A.C. VERAFLOR™ Therapy with V.A.C. VERAFLOR CLEANSE CHOICE™ Dressing. A. Anterior view; B. medial view.



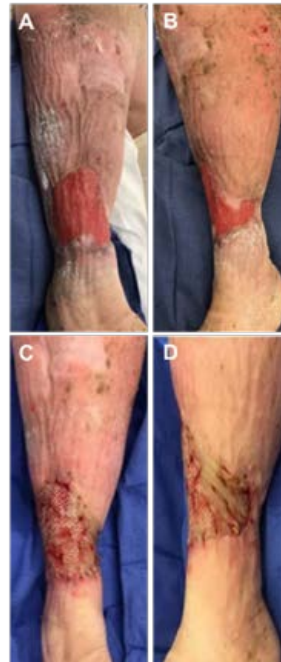The patient was transitioned to V.A.C. VERAFLOR™ Therapy using V.A.C. VERAFLOR CLEANSE CHOICE™ Dressing. Therapy settings included instillation of 22mL of normal saline with a 10-minute dwell time, followed by 2 hours of continuous negative pressure at -125mmHg. After 2 days, healthy granulation tissue development was present (Figure 4).

Fig. 4: Wound after 2 days of V.A.C. VERAFLOR™ Therapy with V.A.C. VERAFLOR™ Dressings. A. Anterior view; B. medial view.



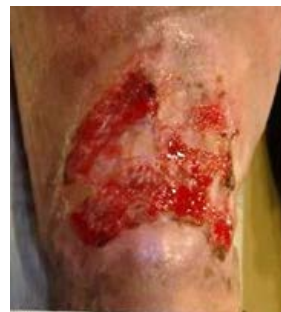V.A.C. VERAFLOR™ Therapy was discontinued and local wound care was initiated using PROMOGRAN™ Matrix Wound Dressing, SILVERCEL™ NON-ADHERENT Antimicrobial Alginate Dressing with EASYLIFT™ Precision Film Technology, an absorptive cover dressing, and four-layer compression dressings. Dressings were changed every 3 days. After 7 days, healthy granulation was observed in the wound bed (Figure 5).

Fig. 5: Wound after 7 days of advanced wound dressing and compression therapy. A. Anterior view; B. medial view.



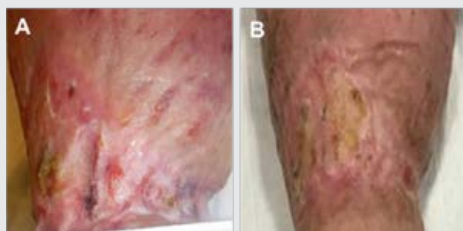
Therapy was changed to SILVERCEL™ NON-ADHERENT Dressing, a second anti-shear absorbent cover dressing, and 4-layer compression dressings. After 4 days, the dressings were removed, and the wound was approved for application of an allograft (Figure 6). TIELLE™ Non Adhesive Hydropolymer Dressing was applied over the graft followed by 4-layer compression dressings.

Fig. 6: Allograft application. A. Wound prior to allograft procedure (anterior view); B. wound prior to allograft procedure (medial view); C. application of allograft (anterior view); D. application of allograft (medial view).



After 2 days, the dressing was switched to ADAPTIC™ Non-Adhering Dressing, SILVERCEL™ NON-ADHERENT Dressing, and 4-layer compression dressings. Dressing changes occurred twice a week. The patient was discharged to a skilled nursing facility for continued care. After 44 days of care, the wound demonstrated areas of reepithelialization (Figure 7).

Fig. 7: Reepithelialization observed in the wound 44 days after grafting.



The wound was fully closed 102 days post grafting and remained closed at a follow-up visit 56 days post closure (Figure 8).

Fig. 8: Wound fully closed. A. Wound fully closed after 102 days of advanced wound dressing care; B. wound remained closed at the follow-up visit (56 days post closure).

Photos and patient information courtesy of Kersten Reider BSN, RN, CWOCN and Elizabeth McElroy, RN, MSN, CRNP, CWS, CWOCN-AP; Tower Health System, West Reading, PA.

Note: As with any case study, the results and outcomes should not be interpreted as a guarantee or warranty of similar results. Individual results may vary, depending on the patient's circumstances and condition.

NOTE: Specific indications, contraindications, warnings, precautions, and safety information exist for all [KCI and/or Systagenix] products and therapies. Please consult a clinician and product instructions for use prior to application. RX only.

Copyright 2018 KCI Licensing, Inc. All trademarks designated herein are proprietary to KCI Licensing, Inc. and Systagenix Wound Management, Limited, its affiliates and/or licensors. PRA-PM-US-0884 (12/18)